

Hypothyroidism Has an Adverse Effect on Human Spermatogenesis: A Prospective, Controlled Study

Gerasimos E. Krassas,¹ Fotini Papadopoulou,¹ Kostas Tziomalos,¹
Theodosia Zeginiadou,² and Nikolaos Pontikides¹

Background: Abnormalities of spermatogenesis are associated with numerous diseases and aging. The objective of this study was to investigate the impact of hypothyroidism on human spermatogenesis and different sperm function tests.

Methods: Twenty-five hypothyroid men and 15 normal individuals were investigated. Semen analysis, fructose and acid phosphatase measurements, teratozoospermia index (TZI), and acridine orange test were determined before and 6–9 months after the initiation of treatment with levothyroxine.

Results: Morphology is the only sperm parameter that differs significantly between hypothyroid patients and controls ($p < 0.0001$). After treatment, morphology improved significantly ($p < 0.001$). Motility was also decreased before treatment in comparison with controls, and improved after treatment. However, the difference was not significant. TZI correlated with free thyroxine.

Conclusions: Hypothyroidism has an adverse effect on human spermatogenesis. Morphology is the only sperm parameter that is significantly affected. Motility may also be affected, but further studies regarding this are needed. Screening for thyroid dysfunction in males who present with a defect in spermatogenesis is strongly recommended, and if hypothyroidism is noted, the response to thyroid hormone should be evaluated before initiating other treatments.

Introduction

HYPER- AND HYPOTHYROIDISM ARE the main thyroid diseases that may have an adverse effect on male reproduction. While the effects of those two entities on female gonadal function are well established (1–5), a few uncontrolled studies with controversial results exist regarding the impact of these diseases on male reproductive function. There are mainly two reasons for this: (a) thyroid diseases are more common in females than in males, and (b) signs and symptoms related to male gonadal function might be obscured by the systemic effects of hypothyroidism.

Recently, it has been reported that hypothyroidism in males is associated with erectile dysfunction and that treatment of thyroid dysfunction restores erectile function (6).

The aim of this controlled, prospective study was to investigate the effect of hypothyroidism on sperm quality and composition, and also on different sperm parameters such as fructose (FR), acid phosphatase, teratozoospermia index (TZI), and acridine orange test (AOT) in hypothyroid male patients before and after attainment of euthyroidism. Similar data,

to the best of our knowledge, have not been published previously.

Materials and Methods

Patients

Thirty-five male patients (mean age 44.1 ± 13.7 , range 18–65 years), all attending the thyroid outpatient clinic of Panagia General Hospital (Thessaloniki, Greece), were recruited for the study; 3 refused to participate, 4 did not attend the final appointment, and 3 did not produce sperm at their initial visit, making the total number 25. Twenty of those were married with children, one married without children, and four unmarried. None of the patients had any serious illnesses in the past year nor were taking any medication on a permanent basis. Eleven out of 25 were smokers (≥ 20 cigarettes daily), and all had normal alcohol consumption. Moreover, no patient had any known fertility problem, and semen analysis was performed in all patients for the first time. Free testosterone (FTesto) and prolactin (PRL) were normal in all patients and controls. All patients were clinically hypothyroid,

¹Department of Endocrinology, Diabetes and Metabolism, Panagia General Hospital, Thessaloniki, Greece.

²Andrology Laboratory, Euromedica, Thessaloniki, Greece.

TABLE 1. PRE- AND POSTTREATMENT PARAMETERS IN PATIENTS WITH CLINICAL HYPOTHYROIDISM AND CONTROLS

Parameter	Normal range	Patients (n = 25)	Posttreatment (n = 25)	Controls (n = 15)	p-Value (pretreatment vs. controls)	p-Value (pretreatment vs. posttreatment)
Concentration	>20×10 ⁶ mL	72 (16–88) ^a	70 (15–97)	68 (12–85)	0.57	0.54
Morphology	≥15%	9 (36%) (9–37) ^a	19 (76%) (10–40) ^a	14 (93%) (14–38) ^a	<0.0001	<0.001
Motility	>25%	25 (17–43)	35 (15–44)	31 (14–42)	0.38	0.16
Fructose	>13 μmol/ej	16 (11–21)	15 (11–19)	17 (14–21)	0.18	0.08
Acid phosphatase	>200 U/ej	215 (185–321)	210 (175–300)	211 (190–300)	0.61	0.39
TZI	<1.6	1.3 (1.0–2.1)	1.3 (1.1–1.8)	1.3 (1.1–1.5)	0.17	0.11
AOT	>50% green spermatozoa	85.3 ± 8.5	86.6 ± 8.4	84.4 ± 10.2	NS	NS
TSH	0.3–4.0 mU/L	61.9 (27.3–82.0)	2.7 (1.2–4.2)	2.1 (0.9–4.0)	<0.0001	<0.0001
FT ₄	7–18 pg/mL	5.9 (3.7–6.9)	12.5 (8.2–15.1)	10.9 (8.7–14.7)	<0.0001	<0.0001

^aNumbers within parentheses indicate the range.

TZI, teratozoospermia index; AOT, acridine orange test; TSH, thyrotropin; FT₄, free thyroxine; NS, not significant.

and measurements of serum thyrotropin (TSH) and free thyroxine (FT₄) were consistent with primary hypothyroidism. FT₄ and TSH were measured by radioimmunoassay (RIA) using standard commercial RIA kits (Brahms, Henningsdorf, Germany). Normal range for FT₄ is 7–18 pg/mL, and that for TSH is 0.3–4.0 mU/L. Interassay variation for FT₄ and TSH was 3.6% and 4.3%, respectively. FTesto and PRL were measured by commercial RIA kits (Biosource [Fleurus, Belgium] and Immunotech [Prague, Czech Republic], respectively). The normal range for FTesto is 8.7–54.7 pg/mL, and that for PRL is 60–400 IU/mL. Interassay variation for FTesto and PRL was 4.7% and 5.1%, respectively. Written informed consent was obtained from all patients and control individuals for their participation. The study was approved by the hospital ethics committee and was performed in accordance with the principles of the declaration of Helsinki.

Immediately after the diagnosis of hypothyroidism, semen analysis was performed on all patients after 3–5 days of abstinence from sexual activity. Nineteen patients produced sperm with their first attempt; six with their second. After the semen examination, the patients were put on levothyroxine treatment. About 3 months after the initiation of treatment with levothyroxine, the patients were euthyroid and TSH and FT₄ were normalized. Fifteen normal individuals without any systemic disease, aged 20–65 years (mean age 41.8 ± 12.3, range 20–65 years), most of who were hospital employees and had previously fathered children, except one who was unmarried, were used as controls. Six out of 15 were smokers (≥20 cigarettes daily), and all had normal alcohol consumption. In 16 patients and in all the controls, TZI and AOT were also measured.

Six to 9 months after the initiation of treatment with levothyroxine, the patients were asked to have another sperm examination under the same conditions, and the same parameters were measured. Further, blood was taken after an overnight fast at 8:00 A.M. for FT₄ and TSH measurements. Six out of 15 control individuals also had another sperm examination under the same conditions approximately 1 year after the first one. All the results are presented in Table 1.

Semen analysis

Immediately after the diagnosis of hypothyroidism, semen analysis was performed in all patients after 3–5 days of abstinence

from sexual activity. Semen analysis was performed according to the World Health Organization (WHO) guidelines (7). After evaluation of liquefaction and measurement of the pH, viscosity, and volume, sperm concentration was determined with a hemocytometer (Thoma pipette, Assistant[®], Sondheim/Rhoen, Germany). For morphology evaluation, prestained slides were smeared with a small volume of semen and allowed to air dry (Testsimplents; Roche Diagnostics, Mannheim, Germany). Sperm morphology was determined using Kruger's strict criteria (8). Motility was calculated as percentage of motile sperm by evaluating 200 sperm per sample 60 minutes after semen collection. Semen was classified according to the WHO nomenclature as normozoospermic or pathozoospermic; the latter was further differentiated into oligozoospermia, asthenozoospermia, and teratozoospermia. Results were considered normal when (a) the semen volume was greater than 2 mL, (b) sperm concentration was greater than 20×10⁶ mL, (c) there was more than 25% rapid forward progressive motility, and (d) there was more than 15% spermatozoa normal in morphology (7).

Biochemical tests in semen

There are various biochemical markers of accessory gland function. Fructose is a marker for the seminal vesicles, while acid phosphatase has been used as a marker for the secretory activity of the prostate gland. Fructose was measured by Richterich method (9). Normal level of fructose is >13 μmol per ejaculate. Measurement of acid phosphatase was based on the use of *p*-nitro-phenylphosphate as a substrate (10). Normal value is ≥200 U per ejaculate.

Teratozoospermia index (TZI)

Morphologically abnormal spermatozoa often have multiple defects. When the number of recorded defects is divided by the number of defective spermatozoa, we have the measure called the TZI or multiple anomalies index, which expresses the number of defects present per spermatozoon. The TZI values should read between 1.00 (each abnormal spermatozoon has only one defect) and 3.00 (each abnormal spermatozoon has head, midpiece, and tail defects). Reports have suggested that a TZI of more than 1.6 is associated with lower pregnancy rates in infertile couples (11).

Acridine orange test (AOT)

AOT was used to distinguish between spermatozoa with native DNA (green fluorescence) and single-stranded DNA (orange-red fluorescence) as a marker for abnormal chromatin condensation. Aliquots of 10 μL volume were spread over a clean microscope slides and allowed to air dry. The slides were fixed in Carnoy's solution (1:3 glacial acetic acid/absolute methanols) for 2 hours. Slides were then stained in AO (CI 46005; Sigma Chemical, St Louis, MO) at 2.5 pH for 5 minutes at room temperature in the dark in an aluminium foil-covered 500-mL glass container. After staining, the slides were gently rinsed with deionized water, mounted using phenylenediamine mounting medium, and examined under a fluorescence microscope (Leitz, Oberkochen, Germany) equipped with a 490-nm excitation filter and 530-nm barrier. About 200 spermatozoa from each slide were assessed in 10 individual fields for the presence of orange-red fluorescence. Sperm with normal condensed DNA revealed a distinct green fluorescent color, whereas sperm heads displaying a fluorescent spectrum varying from yellow-green to red were considered as denatured (12).

Statistical analysis

All data were analyzed using the statistical package SPSS (version 12.0; SPSS Inc., Chicago, IL). All results are reported as median and range. The Mann-Whitney test was used for comparisons between groups. The Wilcoxon Signed rank test was used to test the effect of therapy on sperm analysis parameters. Associations between the studied parameters were explored using Spearman's rank order correlation coefficient. In all cases, a two-tailed p -value less than 0.05 was considered significant.

Results

Nine (36%) of the hypothyroid patients had normal morphology spermatozoa that was significantly less ($p < 0.0001$) than controls [14 (93%)] (Fig. 1). After thyroid hormone treatment 19 (76%) of the hypothyroid patients had spermatozoa normal in morphology ($p < 0.001$) when compared with pretreatment findings (Fig. 1). No difference was found between posttreatment findings and controls. There was a tendency for motility to be improved after treatment (25% to 35%), but this finding was not significant. We also found that TZI correlated significantly with FT_4 levels at baseline ($r = -0.49$, $p < 0.01$) (Fig. 2). Fructose correlated significantly with motility at baseline in controls ($r = 0.79$, $p < 0.001$). Regarding controls, no significant difference was found in morphology (27% vs. 29%) and motility (31% vs. 30%) between the first sample and second sample in the six individuals investigated.

Discussion

The role of thyroid hormone in testicular development and function has received much attention because of the report that functional thyroid hormone receptors are present in high quantities in neonatal Sertoli cells (13–15). These findings changed the classical view of the testis as a thyroid hormone unresponsive organ, suggesting that thyroid hormone could have direct effects on testis. The above data together with the reported high levels of expression of functional triiodothyro-

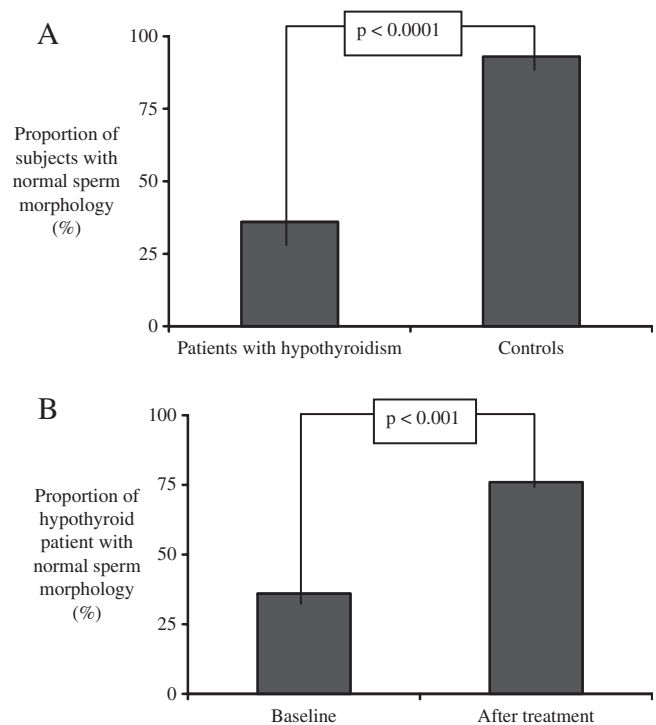


FIG. 1. (A) Proportion of hypothyroid patients with normal sperm morphology at baseline in comparison with controls and (B) before and after treatment.

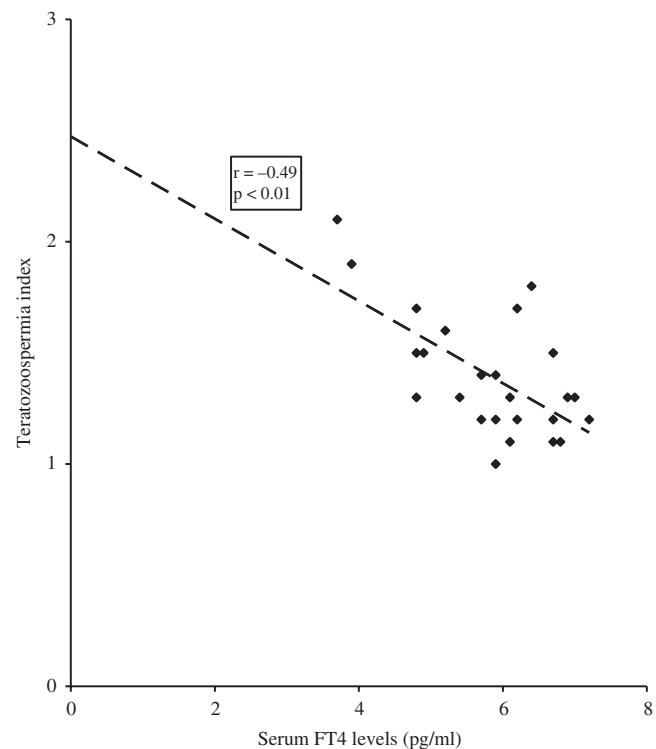


FIG. 2. Correlation between teratozoospermia index and serum free thyroxine (FT_4) levels in patients with hypothyroidism at baseline.

nine receptors in proliferating Sertoli cells (16,17) indicate that Sertoli cells are a major testicular target for thyroid hormone. It appears that thyroid hormone acts directly on Sertoli cells to inhibit proliferation while stimulating differentiation, not only in rodents (18–20) but also in many other vertebrate species (21–25). Although several factors are presumed to play a role in proliferation and maturation of Sertoli cells (26,27), triiodothyronine is likely to represent a major hormonal signal involved in the establishment of the adult Sertoli cell population.

Moreover, Maran and Aruldas (28) found that hypothyroidism significantly reduced seminiferous tubule and lumen diameter in the Wistar rat. Control rats showed active spermatogenesis, whereas in hypothyroid rats, the proliferation and differentiation of germ cells were arrested and their number was decreased. The absolute weight of testes was decreased irrespective of age. The same was found for ventral prostate relative weight. They concluded that hypothyroidism adversely affects spermatogenesis.

Few studies have been published in humans reporting the effect of hypothyroidism on semen quality. In such patients attention usually is focused on other manifestations of the disease, and fertility status is frequently not evaluated. Griboff (29) investigated five patients with primary hypothyroidism aged between 30 and 64 years. All demonstrated normal sperm counts. De la Balze *et al.* (30) investigated six adult male hypothyroid patients aged between 17 and 59 years. All patients demonstrated features of hypogonadotropic hypogonadism. Testicular biopsies revealed histological abnormalities in all patients. Wortsman *et al.* (31) investigated eight hypothyroid male patients aged 37–77 years. All patients had evidence of hypogonadism. Seven out of eight patients had varying degrees of testicular atrophy. Sperm analyses were not performed. Corrales Hernandez *et al.* (32) studied spermatogenesis in 10 patients with a history of hypothyroidism treated with levothyroxine. A decrease in seminal volume, progressive forward motility, and cumulative percentage of mobile forms were observed compared with controls. Induction of hypothyroidism did not lead to seminal changes compared with the same patients during euthyroidism. They concluded that short-term postpubertal hypothyroidism does not cause seminal alterations sufficiently intense to impair male fertility. Jaya Kumar *et al.* (33) studied reproductive and endocrine function of eight males with primary hypothyroidism before and after treatment with levothyroxine. Semen analysis was performed in five out of eight patients, but these data were not presented, although the authors claimed that “some improvement in sperm count and motility was observed.”

Abnormal sperm morphology in hypothyroid males, to the best of our knowledge, has not been published thus far, and could be explained by a direct effect of thyroid hormone on spermatogenesis (34).

Another interesting finding of the present study is that TZI or multiple anomalies index was less than 1.6 in our hypothyroid patients. It has been shown that the best prognostic indicator of infertility is given by the percentage of motile sperm and the TZI, particularly in patients with primary infertility (11). Because TZI is normal in our hypothyroid male patients, it could be suggested that fertility is not disturbed.

Finally, AOT was found to be normal in our hypothyroid patients, and no differences were found in comparisons with

controls. AOT (12) is a technique that evaluates the degree of nuclear chromatin condensation. Acridine orange fluoresces green when it intercalates as a monomer into native DNA (double stranded) and red when it binds to denatured DNA (single stranded) as an aggregate. Acridine orange staining has been suggested as a screening test to evaluate DNA damage in human sperm and to predict fertilization rates (12). It has been observed that men who ejaculate >50% green spermatozoa have significantly high fertilization ability in conventional IVF compared with that of immature cases (35). Our hypothyroid patients ejaculated >50% green spermatozoa, a finding that is similar to the control individuals and suggests that no DNA damage in human sperm is produced by hypothyroidism.

The conclusion of this study is that hypothyroidism has an adverse effect on human spermatogenesis. Morphology is the main sperm parameter that is significantly affected. Motility also is affected, but at a nonsignificant level. Combining these results with those of previous studies that have shown that hyperthyroidism also produced abnormalities in seminal parameters, mainly sperm motility (36), it could be concluded that thyroid dysfunction has an adverse effect on male spermatogenesis. Screening for hypothyroidism in men presenting with sperm abnormalities is strongly recommended, therefore. If hypothyroidism is noted, it should be treated before other treatment modalities are instituted unless there is an excellent rationale such as in patients with pituitary failure.

Acknowledgments

The excellent secretarial assistance of Mrs. Anna Gialantzi is very much appreciated.

Disclosure Statement

No competing financial interests exist.

References

1. Krassas GE, Pontikides N, Kaltsas T, Papadopoulou P, Battrinos M 1994 Menstrual disturbances in thyrotoxicosis. *Clin Endocrinol (Oxf)* **40**:641–644.
2. Krassas GE, Pontikides N, Kaltsas T, Papadopoulou P, Paunkovic J, Paunkovic N, Duntas LH 1999 Disturbances of menstruation in hypothyroidism. *Clin Endocrinol (Oxf)* **50**: 655–659.
3. Krassas GE 2000 Thyroid disease and female reproduction (modern trends). *Fertil Steril* **74**:1063–1070.
4. Krassas GE 2000 Thyroid disease, menstrual function and fertility. *Thyroid Int* **1**:1–11.
5. Krassas GE 2005 The male and female reproductive system in thyrotoxicosis. In: Braverman LE, Utiger RD (eds) *Werner's and Ingbar: The Thyroid. A Fundamental and Clinical Text*. Ninth edition. Lippincott and Co., Philadelphia, pp 621–628.
6. Krassas GE, Tziomalos K, Papadopoulou F, Pontikides N, Perros P 2008 Erectile dysfunction in patients with hyper- and hypothyroidism: how common and should we treat? *J Clin Endocrinol Metab* **93**:1815–1819.
7. WHO Laboratory 1992 Manual for the Examination of Human Semen and Sperm-Cervical Mucus Interaction. Third edition. Cambridge University Press, Cambridge.
8. Kruger TF, Menkveld R, Stander FS, Lombard CJ, van der Merwe JP, van Zyl JA, Smith K 1986 Sperm morphologic features as a prognostic factor in *in vitro* fertilization. *Fertil Steril* **46**:1118–1123.

9. Richterich R 1969 Theory and Practice in Clinical Chemistry. Second edition. Academic Press, New York, pp 477–482.
10. Heite HJ, Wetteraurer W 1979 Acid phosphatase in seminal fluid: method estimation and diagnostic significance. *Andrologia* **11**:113–122.
11. Jouannet P, Ducot B, Feneux D, Spira A 1988 Male factors and the likelihood of pregnancy in infertile couples. I. Study of sperm characteristics. *Int J Androl* **11**:379–394.
12. Tejada RI, Mitchel JC, Mark JJ, Friedman S 1984 A test for the practical evaluation of male fertility by acridine orange fluorescence. *Fertil Steril* **42**:87–91.
13. Palmero S, Prati M, Barreca A, Minuto F, Giordano G, Fugassa E 1990 Thyroid hormone stimulates the production of insulin-like growth factor I (IGF-I) by immature rat Sertoli cells. *Mol Cell Endocrinol* **2**:61–65.
14. Jannini EA, Olivieri M, Francavilla S, Gulino A, Ziparo E, D'Armiento M 1990 Ontogenesis of the nuclear 3,5,3'-triiodothyronine receptor in the rat testis. *Endocrinology* **126**:2521–2526.
15. Francavilla S, Cordeschi G, Properzi G, Di Cicco L, Jannini EA, Palmero S, Fugassa E, Loras B, D'Armiento M 1991 Effect of thyroid hormone on the pre- and post-natal development of the rat testis. *J Endocrinol* **129**:35–42.
16. Buzzard JJ, Morrison JR, O'Bryan MK, Song Q, Wreford NG 2000 Developmental expression of thyroid hormone receptors in the rat testis. *Biol Reprod* **62**:664–669.
17. Jannini EA, Crescenzi A, Rucci N, Screponi E, Carosa E, de Matteis A, Macchia E, d'Amati G, D'Armiento M 2000 Ontogenetic pattern of thyroid hormone receptor expression in the human testis. *J Clin Endocrinol Metab* **85**:3453–3457.
18. Cooke PS, Meisami E 1991 Early hypothyroidism in rats causes increased adult testis and reproductive organ size but does not change testosterone levels. *Endocrinology* **129**:237–243.
19. Joyce KL, Porcelli J, Cooke PS 1993 Neonatal goitrogen treatment increases adult testis size and sperm production in the mouse. *J Androl* **14**:448–455.
20. Kirby JD, Jetton AE, Ackland JF, Turek FW, Schwartz NB 1993 Changes in serum immunoreactive inhibin-alpha during photoperiod-induced testicular regression and recrudescence in the golden hamster. *Biol Reprod* **49**:483–488.
21. Jannini EA, Ulisse S, D'Armiento M 1995 Thyroid hormone and male gonadal function. *Endocr Rev* **16**:443–459.
22. Kirby JD, Mankar MV, Hardesty D, Kreider DL 1996 Effects of transient prepubertal 6-N-propyl-2-thiouracil treatment on testis development and function in the domestic fowl. *Biol Reprod* **55**:910–916.
23. Majdic G, Snoj T, Horvat A, Mrkun J, Kosec M, Cestnik V 1998 Higher thyroid hormone levels in neonatal life result in reduced testis volume in postpubertal bulls. *Int J Androl* **21**:352–357.
24. Matta SL, Vilela DA, Godinho HP, França LR 2002 The goitrogen 6-n-propyl-2-thiouracil (PTU) given during testis development increases Sertoli and germ cell numbers per cyst in fish: the tilapia (*Oreochromis niloticus*) model. *Endocrinology* **143**:970–978.
25. Jansen HT, Kirby JD, Cooke PS, Arambepola N, Iwamoto GA 2007 Impact of neonatal hypothyroidism on reproduction in the male hamster, *Mesocricetus auratus*. *Physiol Behav* **90**:771–781.
26. Sharpe RM, McKinnell C, Kivlin C, Fisher JS 2003 Proliferation and functional maturation of Sertoli cells, and their relevance to disorders of testis function in adulthood. *Reproduction* **125**:769–784.
27. Mackay S, Smith RA 2007 Effects of growth factors on testicular morphogenesis. *Int Rev Cytol* **260**:113–173.
28. Maran RR, Aruldas MM 2002 Adverse effects of neonatal hypothyroidism on Wistar rat spermatogenesis. *Endocr Res* **28**:141–154.
29. Griboff SI 1962 Semen analysis in myxedema. *Fertil Steril* **13**:436–443.
30. De la Balze FA, Arrilaga F, Mancini RE, Janches M, Davidson OW, Gurtman AI 1962 Male hypogonadism in hypothyroidism: a study of six cases. *J Clin Endocrinol Metab* **22**:212–222.
31. Wortsman J, Rosner W, Dufau ML 1987 Abnormal testicular function in men with primary hypothyroidism. *Am J Med* **82**:207–212.
32. Corrales Hernandez JJ, Miralles Garcia JM, Garcia Diez LC 1990 Primary hypothyroidism and human spermatogenesis. *Arch Androl* **25**:21–27.
33. Jaya Kumar B, Khurana ML, Ammini AC, Karmarkar MG, Ahuja MM 1990 Reproductive endocrine functions in men with primary hypothyroidism: effect of thyroxine replacement. *Horm Res* **34**:215–218.
34. Wagner M, Magagin S, Maia AL 2008 The role of thyroid hormone on testicular development and function. *J Endocrinol*. Aug 26 [Epub ahead of print].
35. Hoshi K, Katayose H, Yanagida K, Kimura Y, Sato A 1996 Relationship between acridine orange fluorescence of mammalian sperm nuclei and the fertilizing ability of human sperm. *Fertil Steril* **66**:634–639.
36. Krassas GE, Pontikides N, Deligianni V, Miras K 2002 A prospective controlled study of the impact of hyperthyroidism on reproductive function in males. *J Clin Endocrinol Metab* **87**:3667–3671.

Address reprint requests to:

Gerasimos E. Krassas, M.D., Ph.D., FRCP (Lond)
 Department of Endocrinology, Diabetes and Metabolism
 Panagia General Hospital
 N.Plastira 22, N. Krini
 Thessaloniki 55132
 Greece

E-mail: krassas@the.forthnet.gr

This article has been cited by:

1. Marcia Santos Wagner, Simone Magagnin Wajner, Ana Luiza Maia. 2009. Is there a role for thyroid hormone on spermatogenesis?. *Microscopy Research and Technique* **72**:11, 796-808. [[CrossRef](#)]